

Screening Reference Guide

General Screening Rules:

- Do not leave any questions unanswered.
- When in doubt, be conservative!
- If you are not sure a condition is present, assume it is not.
- A broken or chipped tooth is sound unless obvious decay is found.



Missouri
Department of
Health & Senior
Services

Office of Dental
Health



Preventive Services Program

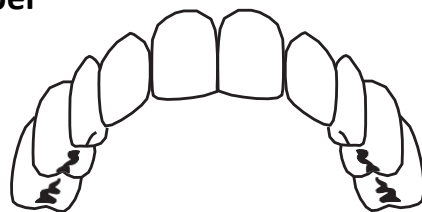
Website: psp.health.mo.gov

573-751-5874 or 800-891-7415

An EO/AA employer: Services provided on a non-discriminatory basis. Individuals who are deaf, hard-of-hearing, or have a speech disability can dial 711 or 1-800-735-2966.

Primary Dentition

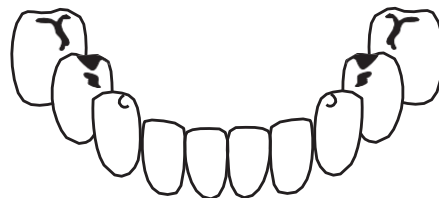
Upper



	<i>Eruption</i>	<i>Shedding</i>
Central Incisor	7 1/2 mos.	7 1/2 yrs.
Lateral incisor	9 mos.	8 yrs.
Canine	18 mos.	11 1/2 yrs.
First Molar	14 mos.	10 1/2 yrs.
Second Molar	24 mos.	10 1/2 yrs.

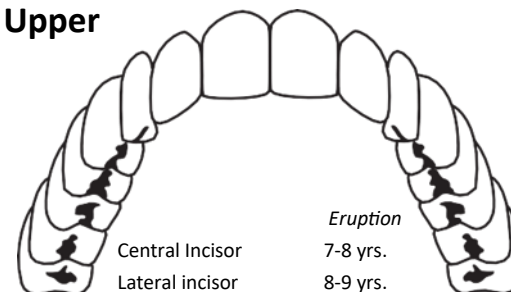
Lower

	<i>Eruption</i>	<i>Shedding</i>
Central Incisor	6 mos.	6 yrs.
Lateral incisor	7 mos.	7 yrs.
Canine	16 mos.	9 1/2 yrs.
First Molar	12 mos.	10 yrs.
Second Molar	20 mos.	11 yrs.



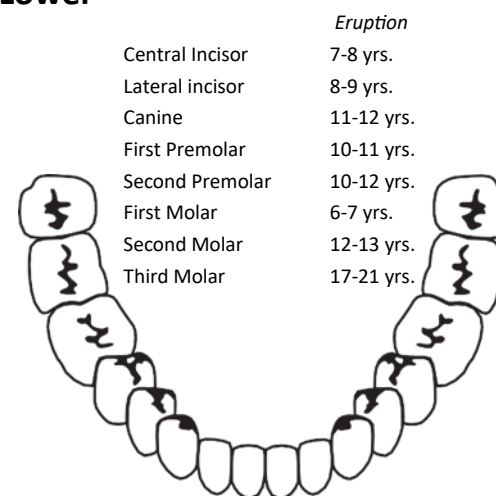
Permanent Dentition

Upper



	<i>Eruption</i>
Central Incisor	7-8 yrs.
Lateral incisor	8-9 yrs.
Canine	11-12 yrs.
First Premolar	10-11 yrs.
Second Premolar	10-12 yrs.
First Molar	6-7 yrs.
Second Molar	12-13 yrs.
Third Molar	17-21 yrs.

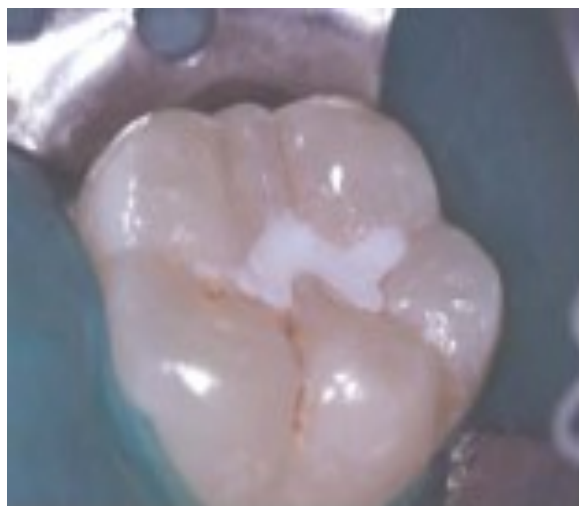Lower



	<i>Eruption</i>
Central Incisor	7-8 yrs.
Lateral incisor	8-9 yrs.
Canine	11-12 yrs.
First Premolar	10-11 yrs.
Second Premolar	10-12 yrs.
First Molar	6-7 yrs.
Second Molar	12-13 yrs.
Third Molar	17-21 yrs.

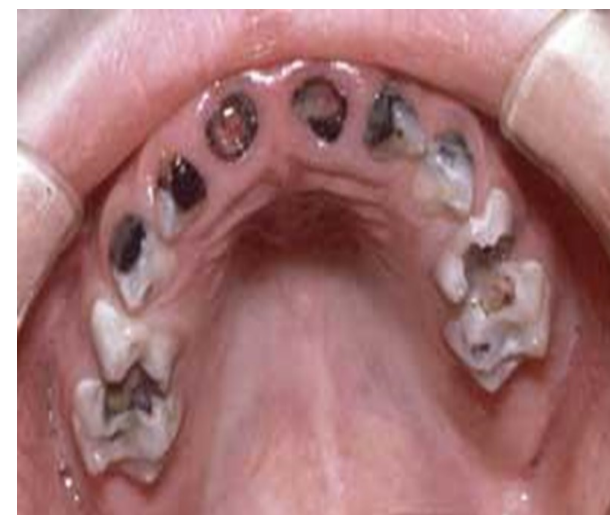6. Presence of Sealants

Count all sealants whether partially retained or completely retained



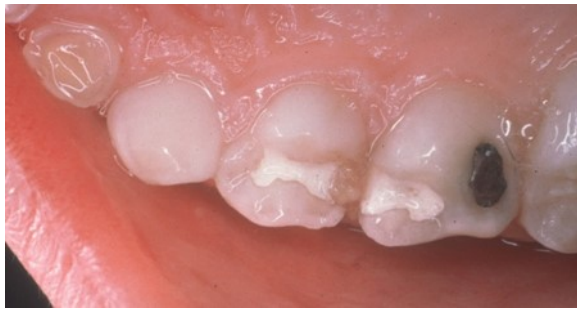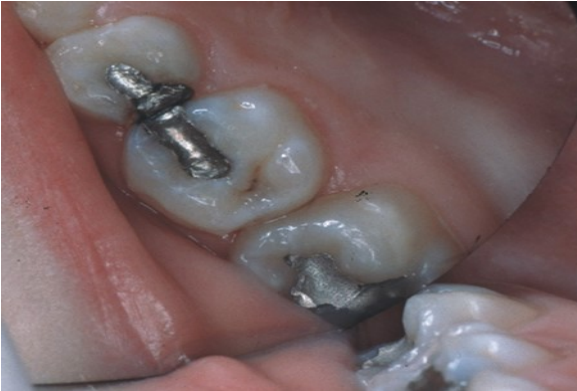7. History of Rampant Caries

Decay on 7 or more teeth



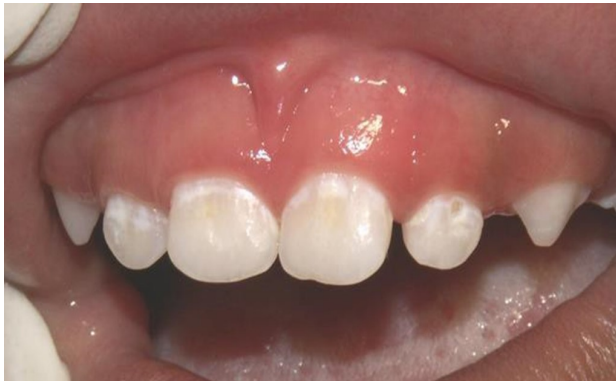8. Treated Decay

Restorations, crowns, or pulpotomy must be due to decay, not due to an injury.



11. White Spot Lesions

Caries history ONLY on primary maxillary anteriors

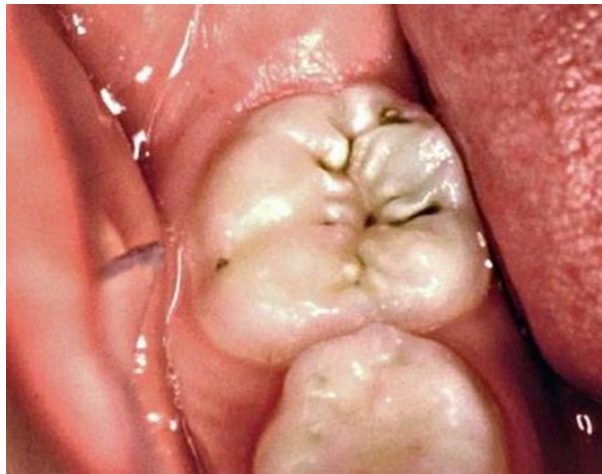


<http://earlychildhoodcariesresourcecenter.elsevier.com>

We appreciate your participation in the dental screenings. Thank you for investing your time in the community's efforts to improve the oral health of all Missouri children!

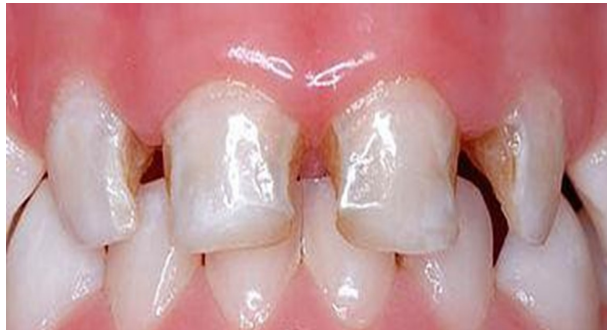9. Untreated Decay

Decay is a loss of at least 1/2 mm or tooth structure at the enamel surface and darkening coloration of the tooth structure



12. Early Childhood Caries

Caries history ONLY on primary maxillary anteriors



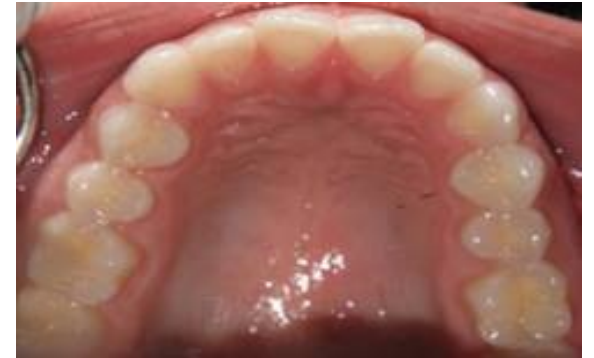<http://www.babydds.com/pediatric-dental-topics>

This guide was designed using a modified format of the Basic Screening Survey from the Association of State and Territorial Dental Directors.

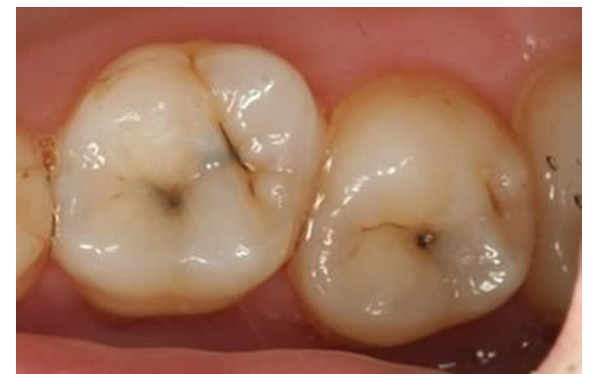Some of the photos credits: University of Missouri -Kansas City, School of Dentistry; Ohio Department of Health, Dr. Craig Hollander, Dr. Bhalajhi Iyyer; or as indicated by website links below the photo.

10. Treatment Urgency

No Obvious Problem



Early Dental Care



<http://modemdentistry.com.au/images>

Urgent Care

